



**PATIENT**

Chloe Stormo-Sceva

**SPECIES**

Canine

**BREED**

Parsons Terrier

**SEX**

Female Spayed

**AGE**

12 years

**WEIGHT**

15lbs

**INTERPRETED BY**

Maggie Machen  
 Lamy, DVM, DACVIM  
 (Cardiology)

**IMAGING PERFORMED BY**

Sara Hansen

**HOSPITAL NAME**

VCA Mckenzie  
 Animal Hospital

**REFERRING VET**

Dr. Arpaia

**INVOICE**

23249

**DATE**

3/23/22

**PRESENTING CLINICAL SIGNS**

History: Progressive heart murmur - Grade 2/6 in 2018; Grade 3/6 at last exam March 2022.  
 -Abnormal PE/Chem/CBC/UA Results: CBC - WNL. Chemistry profile - Superchem: WNL except - ALT 211 (12-118) - ALP 162 (5-131) - BUN 41 (6-31); Heartworm test - Neg.  
 -Current medications: Supplements: joint supplement and fish oil.

**ELECTROCARDIOGRAPHIC FINDINGS** \*Note: Single lead ECGs are evaluated as a rhythm strip. Morphology/MEA cannot be definitively commented on.

A single lead ECG is available; 50mm/s, 20mm/mV. The average heart rate is 140bpm (range 100-188bpm). The rhythm is sinus in origin, with a p for every QRS complex and vice versa. The P and QRS morphologies are positive. No ectopic beats, pauses or dysrhythmias observed.  
 ECG diagnosis: Normal sinus rhythm with respiratory variation.

**ECHOCARDIOGRAM FINDINGS**

2D, m-mode, color flow and doppler imaging is available. Diffuse thickening of mitral valve leaflets (anterior>posterior) with mild prolapse into the left atrial lumen. Moderate eccentric mitral regurgitation with moderate left atrial dilation. Normal MR velocity. Borderline LV with adequate myocardial function. The tricuspid valve appears thickened with mild prolapse and mild tricuspid regurgitation. Normal velocity. Normal right atrial and ventricular diameter. The pulmonic and aortic valves are normal in morphology and mobility. Normal pulmonic and aortic outflow velocities. No aortic and mild pulmonic insufficiency. No pericardial or pleural effusion noted. No cardiac tumors observed.

**CARDIAC CHART**

CANINE CARDIAC PARAMETERS	MR VMAX (m/s)	TR VMAX (m/s)	LA/AO (Boon method)	LA/AO (Heart Base; Swe)	FS (%)	EF (%)	EPSS (cm)
NORMAL PARAMETER	4.5-5.5	<2.7	1.3	<1.6	28-40	40-100	<0.6
PATIENT	4.9	2.5	1.3	1.7	48	90	0.2
CANINE CARDIAC PARAMETERS	HR (BPM)	AV VMAX (m/s)	PV MAX (m/s)	BODY WEIGHT (kg)	LA 2D short axis Base view (cm)	LVIDd Avg; 2D and m-mode short axis (cm)	LVIDs Avg; 2D and m-mode short axis (cm)
NORMAL PARAMETER	50-100	0.7-1.7	0.7-1.6	BELOW	BELOW	BELOW	BELOW
PATIENT	140	1.2	0.8	6.8	2.6	2.9	1.5
*Normal chamber parameters expressed as a mean value (SD)				3	1.27 (5.3)	2.46 (2.46)	1.36 (5.5)
<b>BODY WEIGHT DEPENDENT PARAMETERS</b>				5	1.40 (4.5)	2.74 (5.2)	1.60 (4.7)
				10	1.50 (3.8)	3.27 (3.5)	2.06 (3.1)
Adapted from June Boon, Veterinary Echocardiography, 1998				15	1.83 (2.0)	3.71 (2.4)	2.43 (2.1)
Rishniw M and Hollis NE, J Vet Intern Med 2000; 14:429-435				20	2.02 (1.9)	4.14 (2.2)	2.80 (2.0)
Hansson et al, Vet Rad and Ultrasound 2002				25	2.18 (2.4)	4.48 (2.9)	3.10 (2.5)
Bonagura et al. Echocardiography: principles of interpretation, Vet Clin North Am 15:1177, 1995				30	2.33 (3.3)	4.83 (3.9)	3.39 (3.4)
				35	2.48 (4.3)	5.17 (5.0)	3.69 (4.5)



**PATIENT**

Chloe Stormo-Sceva

	40	2.62 (5.2)	5.48 (6.1)	3.96 (5.4)
	50	2.88 (7.1)	6.07 (8.3)	4.46 (7.4)

**SPECIES**

Canine

**INTERPRETATION OF THE FINDINGS & FURTHER RECOMMENDATIONS**

Chronic degenerative valve disease causing moderate mitral and mild tricuspid regurgitation. Moderate left atrial enlargement indicates there is relatively low risk for imminent complication, however risk for progression to spontaneous congestive heart failure in the future is elevated. No additional issues are identified. The ECG is unremarkable with a normal sinus rhythm.

**BREED**

Parsons Terrier

Given the risk for progression and results of the EPIC trial, Pimobendan is indicated in this patient as below. Assessment of progression in the future will help predict long term outcome, however prognosis is guarded at this stage (B2).

**SEX**

Female Spayed

Omega fatty acid supplementation and mild salt restriction may also be of some long-term benefit. Monitor for development of a progressive cough, labored breathing, exercise intolerance or collapse episodes.

**AGE**

12 years

Once on the medication for 3-5 days, anesthetic risk is considered mildly elevated. Cardiac protective drug choices (opioid/benzodiazepine premedication, Propofol or alfaxalone induction, iso or sevo gas) are recommended. Monitor for arrhythmias, hypotension, and hypoxia both intra and post-operatively and intervene as necessary. Judicious IV fluid rates are recommended to avoid fluid overload. Avoid heart rate stimulating drugs such as atropine unless clinically indicated.

**WEIGHT**

15lbs

**INTERPRETED BY**

Maggie Machen  
Lamy, DVM, DACVIM  
(Cardiology)

**PLAN**

Baseline BP recommended. Institute heart muscle support Pimobendan 0.25-0.3mg/kg PO q12h.

Recommend monitor for progression with a recheck echocardiogram in 6 months, sooner if any development of clinical signs.

**IMAGING PERFORMED BY**

Sara Hansen

**HOSPITAL NAME**

VCA Mckenzie  
Animal Hospital

**REFERRING VET**

Dr. Arpaia

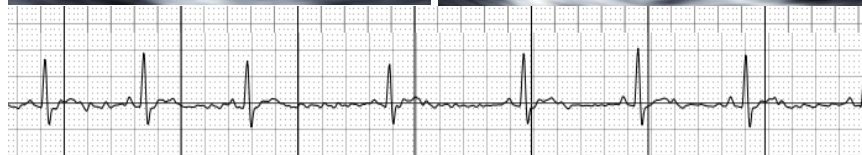
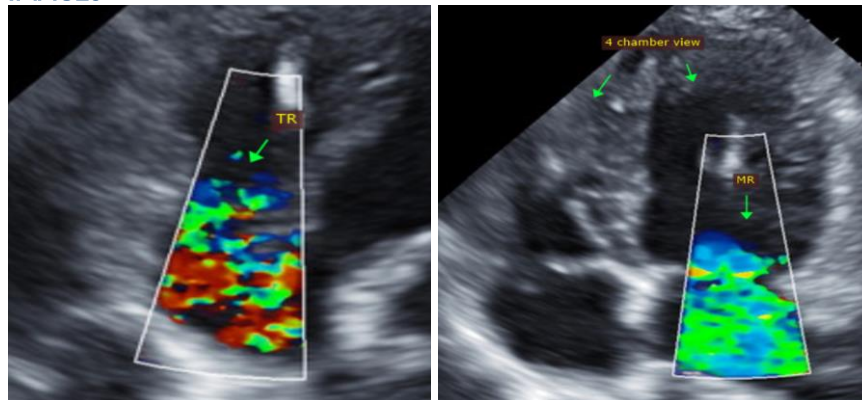
**INVOICE**

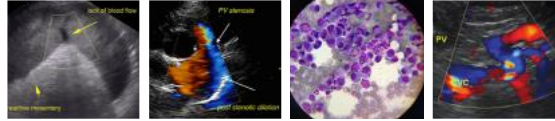
23249

**DATE**

3/23/22

**IMAGES**





**PATIENT**

Chloe Stormo-Sceva

The information and recommendations provided are based on the images presented by the referring veterinarian. No evaluation can be communicated regarding pathology that was not visible in the image/video clips provided.

**SPECIES**

Canine

Thank you for this referral. This report was generated using transcription software, and minor dictation errors may be present. If the clinical or image interpretation does not parallel your findings or if I can be of any further assistance, please contact me.

**BREED**

Parsons Terrier

**Maggie Machen Lamy, DVM**  
Diplomate of the American College of Veterinary Internal Medicine (Cardiology)  
info@sonopath.com

**SEX**

Female Spayed

**AGE**

12 years

**WEIGHT**

15lbs

**INTERPRETED BY**

Maggie Machen  
Lamy, DVM, DACVIM  
(Cardiology)

**IMAGING  
PERFORMED BY**

Sara Hansen

**HOSPITAL NAME**

VCA Mckenzie  
Animal Hospital

**REFERRING VET**

Dr. Arpaia

**INVOICE**

23249

**DATE**

3/23/22